

Las Variaciones Nerviosas del Miembros Superior Pueden Alterar el Diagnóstico Clínico

Scafoglieri, Aldo; Wynant, Ellen; Héréus, Savannah; Van den Broeck, Jona; Cattrysse, Erik

Published in:

International journal of morphology

DOI:

[10.4067/S0717-95022023000200555](https://doi.org/10.4067/S0717-95022023000200555)

Publication date:

2023

License:

CC BY-NC

Document Version:

Final published version

[Link to publication](#)

Citation for published version (APA):

Scafoglieri, A., Wynant, E., Héréus, S., Van den Broeck, J., & Cattrysse, E. (2023). Las Variaciones Nerviosas del Miembros Superior Pueden Alterar el Diagnóstico Clínico: Una Revisión de Alcance. *International journal of morphology*, 41(2), 555-568. <https://doi.org/10.4067/S0717-95022023000200555>

Copyright

No part of this publication may be reproduced or transmitted in any form, without the prior written permission of the author(s) or other rights holders to whom publication rights have been transferred, unless permitted by a license attached to the publication (a Creative Commons license or other), or unless exceptions to copyright law apply.

Take down policy

If you believe that this document infringes your copyright or other rights, please contact openaccess@vub.be, with details of the nature of the infringement. We will investigate the claim and if justified, we will take the appropriate steps.

Upper Limb Nerve Variations May Alter Clinical Diagnosis: A Scoping Review

Las Variaciones Nerviosas del Miembros Superior Pueden Alterar el Diagnóstico Clínico: Una Revisión de Alcance

Aldo Scafoglieri^{1,2}; Ellen Wynant¹; Savannah Héréus¹; Jona Van den Broeck¹ & Erik Cattrysse¹

SCAFOGLIERI, A.; WYNANT, E.; HÉRÉUS, S.; VAN DEN BROECK, J. & CATTRYSSSE, E. Upper limb nerve variations may alter clinical diagnosis: A scoping review. *Int. J. Morphol.*, 41(2):555-568, 2023.

SUMMARY: Upper limb nerve variations may be related to the absence of a nerve, an interconnection between two nerves or a variant course. The purpose of this review is to screen the existing literature on upper limb nerve variations that may alter the neurologic diagnostic process. A scoping review was performed following PRISMA for Scoping Reviews guidelines. Initially, 1331 articles were identified by searching Pubmed and Web of Science until the 22nd of October 2022. After screening, reading, and additional searching 50 articles were included in this review. Variations were divided into two categories: 1) variations causing a different innervation pattern involving sensory, motor, or both types of fibers, and 2) variations causing or related to compression syndromes. Two-thirds of the included articles were cadaver studies. Nine articles were diagnostic studies on symptomatic or healthy individuals involving medical imaging and/or surgery. Nerve variations that may cause a different innervation pattern concern most frequently their interconnection. The connection between the median and musculocutaneous nerve in the upper limb and the connection between the median and ulnar nerve in the forearm (Martin-Gruber) or hand (Riche-Cannieu) may be present in half of the population. Injury to these connections may cause compound peripheral neuropathies a result of variant sensory and motor branching patterns. Muscular, vascular, or combined anomalies in the forearm were reported as causes of entrapment neuropathies. These nerve variations may mimic classical entrapment syndromes such as carpal tunnel syndrome or compression at ulnar canal (Guyon's canal). Knowledge of frequent nerve variations in the arm may be important during the diagnostic process and examination. Variant innervation patterns may explain non-classical clinical signs and/or symptoms during provocative tests. Classical nerve compression syndromes in the arm may warrant for differential diagnosis, especially in the case of persistent or recurrent symptoms.

KEY WORDS: Nerve; Anatomical variation; Upper limb; Diagnosis; Pathology.

INTRODUCTION

Mahan & Spinner (2015) described two main types of nerve variations: the first type pertains the course of the nerve itself or its distribution; the second type includes variations in non-nerve anatomies, such as tendons, muscles, or arteries that are related to the course of the nerve. Both types of nerve variations are supposed to have clinical significance (Alraddadi, 2021; Solia *et al.*, 2022). In case the distribution of a nerve differs from its classical distribution, its innervation pattern may partially overlap with that of two different peripheral nerves. For example, the area where the patient may report symptoms could differ from the usual area in case of a nerve injury in the presence of a neural connection between the affected nerve and another

nerve (Soubeyrand *et al.*, 2020; Hemmi *et al.*, 2021). Variations in muscles or fibrous bands have also been related to the development of neuropathies either by compressing the nerve or restricting its movement (Mahan & Spinner, 2015). As peripheral nerves follow their course through the upper limb, they may pierce muscles or ligaments, travel through bony or soft tissue nerve canals, or travel around tendons, all of which may contribute to compression. It has been suggested that nerve variations may alter the clinical presentation of nerve compression (Markeson *et al.*, 2012). For example, the presence of a muscle variation in the forearm may result in a (false) negative provocative test for carpal tunnel syndrome, albeit the patient may report

¹ Experimental Anatomy research group, Faculty of Physical Education and Physiotherapy, Vrije Universiteit Brussel, Laarbeeklaan 103, 1090 Brussels, Belgium.

² SOMT University of Physiotherapy, Softwareweg 5, 3800 Amersfoort, Netherlands.

typical symptoms. Knowledge of these upper limb nerve variations may therefore help to avoid errors in the interpretation of signs and symptoms (Alraddadi, 2021).

In general upper limb nerve variations are rather common (Solia *et al.*, 2022). Although the prevalence of specific nerve variations may be quite variable (Ioannis *et al.*, 2015), the variation in the neural architecture of the brachial plexus for example is known to be more the rule than the exception (Johnson *et al.*, 2010). To the knowledge of the authors, there has not been a comprehensive review describing the clinical implications of upper limb nerve variations. As an understanding of the most common nerve variations may help clinicians to avoid misdiagnosis of nerve pathologies in case of injury and/or chronic compression, the purpose of this scoping review is to map out the existing literature on the upper limb nerve variations that may have clinical implications for the diagnostic process.

MATERIAL AND METHOD

This scoping review was performed following PRISMA for Scoping Reviews guidelines (Tricco *et al.*, 2018).

Eligibility criteria. Articles about upper limb nerve variations and their clinical importance regarding the diagnostic process were included. Articles had to be written in English, Dutch, French, or German. Articles merely describing upper limb nerve variations without discussing or mentioning clinical importance were excluded. There were no limits regarding population, type of intervention, study design, or time. We excluded embryonal, foetal, and/or animal studies.

Information sources. To identify relevant articles for this scoping review, Pubmed and Web of Science were searched until the 20th of October 2022. An electronic search strategy was developed for Pubmed and adapted for Web of Science (See appendix 1 for the entire Medline word string). The string was based on the following mesh terms [(upper extremity) OR (upper limb) OR (arm) AND (variation) AND (nerve)]. No supplementary limits or filters were used. Subsequently, the reference list of the selected articles was studied in detail to identify additional relevant articles. The final results were exported into EndNote (ClarivateTM, Philadelphia, US).

Study selection. After deduplication using Endnote, titles, and abstracts of included records were screened using Rayyan Software (Ouzzani *et al.*, 2016). All remaining articles were then screened by full-text review by one author (EW).

Initially, 2337 articles were identified. After removing the duplicates 1331 articles remained, of which 1241 were excluded based on title and abstract. The remaining articles were read in full text and included based on in- and exclusion criteria. The study selection process can be followed in the PRISMA flow chart (Fig. 1).

Search string . ("upper extremity"[MeSH Terms] OR ("upper"[All Fields] AND "extremity"[All Fields]) OR "upper extremity"[All Fields] OR ("upper extremity"[MeSH Terms] OR ("upper"[All Fields] AND "extremity"[All Fields]) OR "upper extremity"[All Fields] OR ("upper"[All Fields] AND "limb"[All Fields]) OR "upper limb"[All Fields])) AND "vari*"[All Fields] AND "nerv*"[All Fields]

Outcome variables. From each article data on the characteristics of the article (e.g. anatomical region, authors, country, year of publication, and study type) were abstracted. If mentioned in the studies basic characteristics such as the age and sex of the subjects or cadavers were described. The reported anatomical variation(s) and their clinical importance for the diagnostic process were reported.

RESULTS

Study selection. Ninety articles were identified and planned for full-text screening based on our in- and exclusion criteria. Of those, forty-one articles were not relevant for this review, including articles

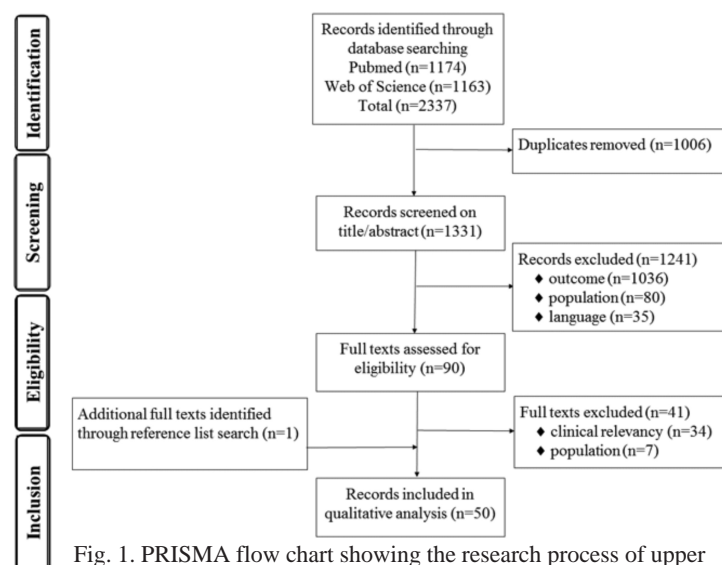


Fig. 1. PRISMA flow chart showing the research process of upper limb nerve variations.

Table 1. Prevalence, innervation pattern and clinical importance of upper limb nerve variations.

Region	Author (Year)	Study type	Sample	Variation (prevalence)	Innervation Pattern	Clinical importance
Upper arm	Günüşburun & Adigüzel (2000)	Cadaver study; case report	72-year-old female	An absence of the musculocutaneous nerve on both sides	The biceps brachii and brachialis muscles were innervated by the median nerve, which also gave off the lateral antebrachial cutaneous nerve	Knowledge of the anatomical variations of the peripheral nerve can explain when encountering an incomprehensible clinical sign
Upper arm	Moore <i>et al.</i> (2020)	Cadaver study; case report	Adult male aged approximately 60 years	The right musculocutaneous nerve was absent	The coracobrachialis, biceps brachii, and brachialis muscles were innervated by the median nerve, which also gave off the lateral cutaneous nerve of the forearm	In cases of injury, knowledge of these variations can help avoid misdiagnosis
Upper arm	Lee <i>et al.</i> (2014)	Cadaver study; case report	61-year-old Korean male	The left musculocutaneous nerve did not pierce the coracobrachialis muscle, but gave 2 muscular branches and had a communicating branch to the median nerve. A supernumerary head of the biceps brachii muscle was present.	The presence of the supernumerary head of the biceps brachii muscle might affect the course and branching of the musculocutaneous nerve	Knowledge of different patterns of the musculocutaneous variation associated with biceps brachii muscle variations is essential for anatomists and clinicians
Upper arm	Krishnamurthy <i>et al.</i> (2007)	Cadaver study	26 right and 18 left formalin-preserved upper limbs	7 of 44 (16%) specimens had connecting branches between the musculocutaneous nerve and the median nerve. In 4 specimens the communicating branches arose from the musculocutaneous nerve, in the other 3 from the median nerve	The interconnection between the nerves may give rise to overlapping symptoms or signs when one is injured	Communications between the musculocutaneous nerve and the median nerve are common making it important to consider their variations during a clinical assessment as they could help explain otherwise incomprehensible clinical findings
Upper arm	Guerrí-Guttenberg & Ingolotti (2009)	Cadaver study + literature review	56 adult upper limbs	In 3.6% of limbs, the musculocutaneous was absent and in 43% there was one communication between the musculocutaneous nerve and the median nerve and in 10.7% there were two communications	Lesions of the median nerve in cases where the musculocutaneous nerve is absent would also lead to unexpected clinical signs, as signs of median and musculocutaneous injury would coexist	The knowledge of these variations will allow physicians to correctly interpret anomalous innervation patterns of the upper limb
Ulnar nerve						
Upper arm and forearm	Gum <i>et al.</i> (2015)	Cadaver study	50 upper limbs from Indian cadavers aged between 45 and 60 years	Ulnar nerve variations were observed in 4 specimens (8%) - A n abnormal formation of the ulnar nerve with a large contribution from the lateral cord of the brachial plexus was seen in two limbs - A n abnormal communication with the radial nerve where the radial nerve gave off a communicating branch to the ulnar nerve before entering the radial groove - A n abnormal communication with the medial cutaneous nerve in the forearm	In the presence of these communicating branches, there might be an inexplicable sensory loss as a result of trauma or surgical intervention	Awareness of ulnar nerve anatomical variation in both its formation and abnormal communication is important for diagnostic approaches and the management of ulnar neuropathy
Wrist and hand	Rogers <i>et al.</i> (1991)	Cadaver study	77 American cadaveric upper limbs	A neural loop in the course of the deep motor branch of the ulnar nerve surrounding the hook of the hamate. Incidence of 9% in the study sample.	In case there is a neural loop present an atypical clinical presentation might be present	The knowledge about these variations of the peripheral nerves is important for clinicians in understanding the severity of neuropathy-related complications.
Hand	Ninisu <i>et al.</i> (2010)	MRI and US study	30 hands of 15 healthy Japanese volunteers (6 male, 9 female) between 21 to 23 years	Variations of branching patterns of the ulnar nerve in Guyon's canal. The branched arborization patterns can be categorized into bifurcation or trifurcation, and their variants. 70% revealed bifurcation and 30% had trifurcation branching pattern of the ulnar nerve.	A superficial and a deep branch were present in the bifurcation pattern, and two superficial and one deep branch in the trifurcation pattern	In cases with atypical clinical presentation after penetrating injuries or compression neuropathy of the ulnar nerve at the wrist, this variation should be considered. Information on ulnar nerve distribution in patients can be instrumental in the diagnosis of a variety of conditions affecting the ulnar aspect of the hand

Median nerve						
R region	Author (year)	Study type	Sample	Variation (prevalence)	Intervention Pattern	Clinical importance
B rachial plexus	Behery (2004)	C adaver study	98 upper limbs of 49 formalin-fixed cadavers from Sri Lanka	Variations of roots in the formation of the median nerve are divided into two types: - T ype I root variation: median nerve with numerical variations of the roots, median nerve formed by three or four roots - T ype II root variation: morphological variation of roots of the median nerve	These variations might create confusing clinical symptoms that could lead to misinterpretation	Knowledge of the presence of different anatomical variations in the formation of the median nerve is important in clinical practice to evaluate nerve injuries
B rachial plexus	Haviarova <i>et al.</i> (2009)	C adaver study: case report	60-year-old man	An atypical course of the median nerve in both upper limbs and different variants in the formation of the median nerve	These variations could be sources of atypical clinical signs as well as electromyographic findings resulting, resulting in diagnostic mistakes	Knowledge of the anatomical variations of peripheral nerves could contribute to explaining atypical clinical signs
B rachial plexus	Ghosh <i>et al.</i> (2022)	C adaver study	60 formalin-fixed upper limbs of 30 cadavers from India	Variation of median nerve formation in 31 % of upper limb specimens: - T hree roots with additional roots from the lateral cord (22 %) - F our roots with additional roots from the lateral and posterior cord (5 %) - A dditional connection with musculocutaneous nerve (3 %)	Variation of the median nerve helps in the diagnosis of peripheral neuropathy in traumatic injuries	Knowledge of such anatomical variations is of interest to the anatomist and clinicians alike. Median nerve variation may lead to confusion in surgical procedures and axillary brachial plexus nerve block anesthesia
B rachial plexus	Butz <i>et al.</i> (2014)	C adaver study: case report	Male cadaver from India	The lateral cord pierced the coracobrachialis muscle and both the musculocutaneous nerve and lateral root of the median nerve branched inferior to the lower attachment of the coraco brachialis muscle on one side. Whereas on the other side the median nerve passes through the flat tendon of the coracobrachialis muscle near its distal insertion into the medial surface of the body of the humerus.	As a variation in the course and branching of the nerve might lead to a variant or dual innervation of a muscle and, if inappropriately compressed, could result in a distal neuropathy	Identification of these variants of brachial plexus plays an especially important role in both clinical diagnosis and surgical practice
B rachial plexus	Passey <i>et al.</i> (2022)	C adaver study	40 cadaveric upper limb specimens from India	Variations in root formation: 1.5 % of the specimen had triple roots, the supernumerary root branching from the lateral cord or medial cord	Injury to supernumerary roots can result in unpredictable neurological deficit	These variations should be considered during regional anesthesia and management of brachial plexus injuries
B rachial plexus	Ongeti <i>et al.</i> (2012)	C adaver study: case report	A 30-year-old male from Kenya	The median nerve was formed by three contributions: two from the lateral cord and one from the medial cord. An additional head of the biceps brachii looped over the formed median nerve making it vulnerable to entrapment.	Symptoms of high median nerve compression arising from similar formations could complicate the symptomatology. They are often confused with more common causes such as radiculopathy and carpal tunnel syndrome.	In this study, the third head of the biceps brachii the median nerve, and a combination of a third contribution of the median nerve with supernumerary heads of the biceps brachii is extremely rare
Forearm	Atoni & Oyinbo (2017)	C adaver study: case report	A 35-year-old male from Nigeria	A splitting of the median nerve in the proximal 1/3 of the forearm forms medial and lateral divisions that accommodate an anomalous muscle. This split median nerve reunifies to continue as a single nerve at the distal 1/3.	A variation in the course and branching of the nerve might lead to variant innervation patterns	Awareness and detailed knowledge of variation in the median nerve and muscles of the forearm are important when diagnosing peripheral neuropathies as they may cause unusual clinical symptoms

The connection between Median and Musculocutaneous nerve

Region	Author (year)	Study type	Sample	Variation (prevalence)	Innervation Pattern	Clinical importance
Upper arm	Oztürk <i>et al.</i> (2010)	Cadaver study; case report	73-year-old male cadaver from Turkey	One-sided communication between the musculocutaneous nerve and the median nerve with multiple variations in the biceps brachii muscle	The communication between the nerves might lead to variant innervation patterns	Knowing different patterns of biceps brachii muscle variations has clinical importance as they also may cause compression of neurovascular structures
Upper arm	Kubwimana <i>et al.</i> (2022)	Cadaver study	3 young adult cases from Rwanda	Communication between the musculocutaneous nerve and median nerve	Entrapment of the musculocutaneous nerve may be challenging as its clinical feature may combine signs of both nerves i.e. weak flexion of the elbow and anesthesia of the lateral forearm and weak flexion of the wrist and fingers	Knowledge of those variations is essential for surgery and regional anesthesia of the upper limbs
Upper arm	Shupak <i>et al.</i> (2018)	Cadaver study	100 upper limbs	In 42 % (23 limbs) communication between the musculocutaneous and the median nerve was present	In case of an injury to the median or musculocutaneous nerve proximal to this anastomotic branch an unexpected presentation of the weakness of the forearm flexor and thenar muscles might be seen or it may present itself as a double nerve injury.	Communication between these nerves is common which is why their presence needs to be determined during a clinical assessment. Lesions of communicating nerve may give rise to a pattern of weakness that may impose difficulty in diagnosis.
Forearm	El Falougy <i>et al.</i> (2013)	Cadaver study	4 adult upper limbs from Slovakia	The musculocutaneous and median nerves were connected by a communicating branch at distinct levels in each cadaver	Combined neuroprathy of the musculocutaneous and median nerves would occur in injuries of the interconnecting branches. Injury to the musculocutaneous and median nerves proximal to these branches might create unexpected symptoms.	These variable interconnecting branches between musculocutaneous and median nerves have to be considered in the diagnosis of nerve lesions in the axillary and arm regions
The connection between Radial and Ulnar nerve						
Region	Author (year)	Study type	Sample	Variation (prevalence)	Innervation Pattern	Clinical interpretation
Upper arm	Naisis <i>et al.</i> (2018)	Cadaver study	133 cadavers from Greece (81 male, 52 female)	An atypical communicating branch originating at a high humeral level from the radial nerve towards the ulnar nerve (incidence 2.3 %). In two cadavers, communicating branches were detected on the left side and in one cadaver bilaterally.	The anastomotic branches, their course, and distribution may lead to entrapment neuropathies. In that case, when the radial nerve or ulnar nerve is injured, the clinical presentation may be unexplained, because the motor or sensory functions remain intact despite matching nerve trauma.	In the case of peripheral neuropathy with a diagnostic dilemma or upper limb nerve injury with otherwise unexpected symptomatology due to the aberrant nerve supply. Familiarity with these variations is crucial in avoiding misdiagnosis.
The connection between the Median and Ulnar nerve (Martin-Gubler connection)						
Region	Author (year)	Study type	Sample	Variation (prevalence)	Innervation Pattern	Clinical interpretation
Forearm	Diz-Diaz <i>et al.</i> (2019)	Cadaver study	50 forearms (13 female) from Spain	The connection was found in 32 % of all cases (16/50)	If present the usual pattern of hand, innervation may be altered because of the distribution of both nerve changes. The Martin-Gubler connection showed mixed sensory and motor connections.	Knowledge of the existence and distribution of this connection is required to optimize the diagnosis and treatment of certain compressive syndromes and median/ulnar nerve injuries
Forearm	Leis <i>et al.</i> (2010)	Case report; electro-diagnostic confirmation	Two symptomatic cases from the USA	Two cases observed with the occurrence of Martin-Gubler (MG) connection combined with anomalous superficial radial innervation to the ulnar dorsum of the hand	Two cases were MG connection and anomalous superficial radial innervation to the ulnar dorsum of the hand resulted in a misdiagnosis of ulnar neuropathy in the forearm and at the elbow	To avoid misdiagnosis of ulnar neuropathy and subsequently an inappropriate treatment, it is important to recognize the coexistence of these two common variants
Forearm	Hefny <i>et al.</i> (2020)	Electrophysiological study	Both forearms of 140 healthy subjects from Egypt	The Martin-Gubler (MG) anastomosis is an anomalous communicating branch between the median nerve and the ulnar nerve in the proximal forearm which can be divided into three types depending on which muscle the cross-over fascicles from the median nerve innervate Type I: the abductor digiti minimi muscle Type II: the first dorsal interosseous muscle Type III: the adductor pollicis and the deep head of the flexor pollicis brevis	The diagnosis of MG anastomosis can be confusing when presented with other pathologies, such as carpal tunnel syndrome. As it can influence the interpretation of motor studies for entrapment neuropathy.	Therefore, awareness and clinical suspicion are important to interpret electrophysiological studies of the ulnar and median nerves

Various nerveconnections						
Region	Author (year)	Study type	Sample	Variation (prevalence)	Intervention Pattern	Clinical interpretation
Forearm and hand	Solia <i>et al.</i> (2022)	Literature review	70 studies	<ul style="list-style-type: none"> Connections in the forearm between the ulnar nerve and radial nerve Connections between the ulnar nerve and median nerve in the forearm (Martin-Gruber, 17%) Connections between the ulnar nerve and median nerve in the hand (Riche-Camilleu or Berretin) 	Ulnar nerve innervated median or radial motor and sensory targets or vice versa	Ignorance of possible existence can lead to misdiagnosis. Most times, aberrant branches lead to entrapment neuropathies. Untypical fibers may not cause an effective nerve block
Hand	Falconer & Spinner (1985)	Cadaver study	10 forearms from the United States of America	<ul style="list-style-type: none"> Transligamentous passages of the recurrent motor branch of the median nerve with multiple branches to the flexor muscle (6%) The Riche-Camilleu anastomosis (3%) Variations in the sensory nerve supply of the median nerve to the thumb 	As these innervation patterns of the hand can differ, the symptoms or signs might be atypical	The differences could be responsible for a certain amount of diagnostic uncertainty when treating a patient with nerve damage
Hand	Hur (2017)	Cadaver study	50 Korean hands aged 20-30 (30 males, 19 females, 1 unknown gender)	<ul style="list-style-type: none"> Diverse variations in innervation patterns of the lumbrical muscles and dual innervation. Whereas the standard textbook explanation of the innervation was not the most common type. 	<ul style="list-style-type: none"> Text: L1 and L2 were innervated by the MN, L3 was innervated by both the MN and the UN, and L4 was innervated by the UN Text: L1 and L2 were innervated by the MN, and L3 and L4 were innervated by the UN. Text: L1, L2, and L3 were innervated by the MN, and L4 was innervated by the UN. Text: L1 was innervated by the MN, L2 was innervated by both the MN and the UN, and L3 and L4 were innervated by the UN. Text: L1 was innervated by the MN, L2, and L3 were innervated by the MN, and L4 was innervated by the UN. Text: L1 was innervated by the MN, L2, and L3 were innervated by the MN and the UN, and L4 was innervated by the UN. Text: L1 and L3 were innervated by the MN, and L2 and L4 were innervated by the UN. 	<ul style="list-style-type: none"> Knowledge of different variations patterns of the lumbrical muscles of the hand will be helpful for an accurate diagnosis and electrophysical examinations in most cases of the median and ulnar nerve.
Hand	Madhavi & Hella (2005)	Cadaver study; case report	Adult male cadaver from South India	<ul style="list-style-type: none"> Dual sensory innervation of the dorsum of the thumb: innervation of the lateral side of the dorsum of the thumb by a dorsal digital nerve from the lateral cutaneous nerve of the forearm; the medial side of the dorsum was innervated by a dorsal digital nerve formed partially by a branch from the lateral cutaneous nerve of the forearm and partially by a dorsal digital branch of the superficial branch of the radial nerve. These two dorsal digital branches of the thumb extended distally beyond the interphalangeal joint to end in the nail bed. The sensory innervation of the dorsum of the hand is variable. There were significant differences in the sensory distribution of the dorsum of the right and left hands of the same cadaver. 	<ul style="list-style-type: none"> A dual innervation of the medial side of the dorsum of the thumb. But the lateral side of the dorsum of the thumb is only innervated by the lateral cutaneous nerve of the forearm. Meaning that an injury to this nerve could lead to a sensory deficit on the dorsolateral aspect of the thumb. 	Awareness of variations in the distribution of the cutaneous nerves to the dorsum of the thumb will help from an accurate diagnosis in case of pain or decreased sensation on the dorsum of the forearm that extends distally beyond the forearm.
Hand	Sulaiman <i>et al.</i> (2015)	Cadaver study	150 adult hands from the United Kingdom	<ul style="list-style-type: none"> Motor and sensory innervation of the hand can be variable. Variations in ulnar nerve branching: bifurcated, trifurcated and anomalous Riche-Camilleu anastomosis Kaplan anastomosis 	<ul style="list-style-type: none"> In case of sensory disturbances or pain at the wrist or dorsum of the hand, knowledge of the sensory distribution of the dorsal cutaneous nerves is needed 	An understanding of the most common innervation pattern and its possible variations is needed to avoid errors when interpreting conduction velocity studies, misdiagnosis of nerve pathology signs and symptoms, and inappropriate treatments.
Hand	Wynner & Dissabandara (2018)	Literature review	Not reported	<ul style="list-style-type: none"> Variations in ulnar nerve branching: bifurcated, trifurcated and anomalous Riche-Camilleu anastomosis Kaplan anastomosis 	<ul style="list-style-type: none"> As these innervation patterns of the hand can differ, the symptoms or signs may be atypical 	Awareness of these variations is needed when interpreting clinical examination findings, electrophysiological and radiological investigations as well as during the management of patients. No knowledge of aberrant connections, innervation, or possible anastomosis means this complex system can never be correctly evaluated.
Hand	Hemmi <i>et al.</i> (2021)	Electrophysiological study	50 hands of 27 healthy adults from Japan	<ul style="list-style-type: none"> Variation in the innervation of the dorsum of the hand: The third finger by the ulnar nerve (5%) The fourth finger by the radial nerve (6%) Dual innervation by the ulnar and radial nerve for the third finger (40%) and fourth finger (5%) 	<ul style="list-style-type: none"> Anatomical variations in the sensory distribution can avoid errors in the interpretation of symptoms 	This knowledge may help clinicians to interpret sensory loss after dorsal hand injuries

MG: Martin-Gruber; MN: Median nerve; UN: Ulnar nerve

without clinical relevance or implications, wrong population (e.g. embryo or foetus), or without relevance for the diagnostic process. An additional relevant article was found through reference screening of the included articles. This resulted in a total of fifty articles that were included in this review. Of the included articles, thirty-six were cadaver studies (of which eighteen case reports), nine articles were diagnostic studies on symptomatic or healthy individuals involving surgery or medical imaging and five were reviews.

The results were divided into two categories. The first category contains articles that described the innervation pattern of upper limb nerve variations (Table I). The second category contains articles on anatomical nerve variations that are of interest in the differential diagnosis of compression or entrapment syndromes (Table II).

Innervation patterns. Thirty articles described nerve variations in which the innervation pattern differed from the normal pattern. These differences in innervation patterns were mainly caused by absence, variable origin, or an unusual connection between nerves.

At their origin in the brachial plexus, the median and ulnar nerves may receive an additional root from the lateral cord in up to 30 % of subjects.

In the upper arm, the musculocutaneous nerve may be absent in 4 % of the population with the median nerve innervating the flexor muscles of the elbow and the skin of the lateral forearm. An abnormal branching pattern of the ulnar nerve was found in 8-9 % of studied samples, with the radial nerve contributing to the ulnar nerve. In up to 50 % of subjects, the musculocutaneous and median nerve may have communicating branches giving rise to overlapping motor and sensory innervation patterns.

In the forearm, the presence of a Martin-Gruber anastomosis (an anomalous communicating branch from the median nerve to the ulnar nerve in the forearm) is being reported in 30 % of the studied samples. When present this variation may cause atypical innervation patterns showing mixed sensory and motor innervation of the forearm and hand.

In the hand, the presence of a Riche-Cannieu anastomosis (an anomalous communicating branch from the deep ulnar nerve to the median motor nerve in the hand) has been described to be present in 30 % of cases. When present, the ulnar nerve may partially or exclusively innervate the thenar muscles. The sensory innervation of the dorsum of the hand is quite variable, with frequent connections between the ulnar and radial nerve.

Differential diagnosis. Twenty articles described anatomical variations that were involved or suspected to cause compression or entrapment of a peripheral nerve.

At the level of the axilla, the median nerve may be compressed by the “arch of Langer” (present in 10 % of subjects), an anomalous muscle or fibrous band connecting the latissimus dorsi muscle to pectoralis major muscle. In this case, symptoms may be similar to 'classical' thoracic outlet syndrome.

In the upper arm, the median nerve may be compressed by the ligament of Struthers, mimicking pronator teres syndrome. Close to the elbow, the ulnar nerve may be compressed by the arcade of Struthers when travelling from the anterior to the posterior compartment, mimicking cubital tunnel syndrome. Occasionally, the musculocutaneous nerve may be entrapped by supernumerary heads of the biceps brachii muscle (Saluja *et al.*, 2017).

In the forearm, the radial nerve may pierce the brachioradialis muscle causing entrapment of its sensory branch. This entrapment may be confused with Wartenberg's syndrome at the level of the anatomical snuffbox (Tryfonidis *et al.*, 2004; Herma *et al.*, 2017). The ulnar nerve may be compressed by the flexor carpi ulnaris muscle, simulating entrapment at ulnar canal (Guyon's canal). Compression of the median nerve may mimic carpal tunnel syndrome. The median nerve may be compressed by an anomalous fibrous or muscular band such as a palmaris longus muscle variant at the mid-forearm, or by an penetrating (ulnar) artery splitting the median nerve.

DISCUSSION

Anatomical variation normally does not influence the function of structures, although it may play an important role in clinical reasoning, e.g. in the diagnostic process. Knowledge of common anatomical variations may be invaluable in clinical practice as they may explain non-classical clinical signs and/or symptoms (Ghosh *et al.*, 2022). Altered innervation patterns are often related to atypical connections between peripheral nerves and are easily overlooked during a clinical examination. These connections or variations are mostly identified during surgery procedures, preoperative imaging, or routine dissection (Alraddadi, 2021).

Connections between nerves. In the brachial plexus, communications between the musculocutaneous and median nerves are very frequently observed (Venieratos &

Table II. Differential diagnosis and clinical interpretation of upper limb nerve variations.

Region	Author (year)	Study type	Sample	Variation	Differential diagnosis	Clinical interpretation
Upper arm	Sajuja <i>et al.</i> (2017)	Cadaver study; case report	64-year-old Indian male	A bilateral tricipital biceps brachii with a variant course of the musculocutaneous nerve. The musculocutaneous nerve did not pierce the coracobrachialis muscle on the right side and terminated by supplying the muscles of the anterior compartment of the arm. However, a normal course was pursued on the left side.	Supernumerary heads of the biceps brachii muscle have been implicated in the compression of surrounding neurovascular structures which could present themselves as symptoms of high median nerve entrapment and thoracic outlet syndrome. A unilateral version of supernumerary heads of the biceps brachii muscle could lead to the misdiagnosis of soft tissue tumors entrapment.	Variations of the musculocutaneous nerve are frequently linked with supernumerary heads of the biceps brachii muscle and often exhibit a modified course. Knowledge of these variations and the associated structures could provide a clinical strategy for diagnosis and necessary and effective management of nerve entrapment.
Radial nerve						
Region	Author (year)	Study type	Sample	Variation	Differential diagnosis	Clinical interpretation
Forearm	Tryfonidis <i>et al.</i> (2004)	Cadaver study	20 Caucasian upper limbs from the UK (7 male, 3 female)	The superficial branch of the radial nerve pierced through the brachioradialis muscle to get to its subcutaneous position in 4 forearm (incidence: 20 %)	This anatomical anomaly could predispose the superficial branch of the radial nerve to compression neuropathy either by the pinching effect on the nerve or by increasing the risk of edema and subsequent fibrosis following chronic mechanical trauma by repeated radial extension-ulnar flexion.	The passing of the superficial branch of the radial nerve through the two parts of a split brachioradialis muscle has potential clinical significance in Wartenberg's syndrome (entrapment of the superficial branch of the radial nerve causing only sensory manifestations). Knowledge of this neuromuscular variant is clinically relevant for the differential diagnosis of pain and paresthesia located on the dorsoradial aspect of the hand
Forearm	Herrn <i>et al.</i> (2017)	Cadaver study; case report	67-year-old French male	The superficial branch of the radial nerve was divided into one branch following an aberrant course between two bellies of the brachioradialis muscle (a superficial one and a deep one with one common origin and one common insertional tendon). This accessory nerve branch was innervated by two blood vessels and pierced through muscle bundles connecting two bellies of the brachioradialis muscle.	This variation of the accessory superficial branch radial nerve branch could cause entrapment of the nerve (Wartenberg's syndrome) in case of muscle hypertrophy due to extensive exercise. This syndrome is often misdiagnosed as the Quervain's tenosynovitis or is not diagnosed at all.	Knowledge of this neuromuscular variant is clinically relevant for the differential diagnosis of pain and paresthesia located on the dorsoradial aspect of the hand
Ulnar nerve						
Region	Author (year)	Study type	Sample	Variation	Differential diagnosis	Clinical interpretation
Upper limb	Polausch <i>et al.</i> (2007)	Literature study	Not reported	The cricariacanal atomy surrounding the cubital tunnel and Guyon canal is emphasized with clinically relevant anatomic variations and muscle anomalies.	The arcade of Struthers is a well-recognized potential site for compression of the ulnar nerve. Anomalous epitrochlear concus muscle has been identified as a possible cause of ulnar nerve compression.	Knowledge of the local, often variable, anatomy is essential for accurate diagnosis and successful treatment of ulnar nerve dysfunction.
Elbow	Campbell <i>et al.</i> (1991)	Cadaver study	130 cadaver elbows	Dense fibrous bands between the olecranon proximal to the cubital tunnel and the medial epicondyle and accessory epitrochlear concus muscles were found in respectively 6 and 14 specimens.	The accessory epitrochlear concus muscle may rarely entrap the ulnar nerve, while the dense fibrous bands or epitrochlear concus ligaments may cause ulnar entrapment. Compression at the flexor carpi ulnaris exit by the deep flexor-pronator aponeurosis could potentially be confused with cubital tunnel syndrome during a surface EMG.	Variability in humeral/ulnar arcade position, anomalous structures, and entrapment at the flexor carpi ulnaris exit are potentially major pit falls in the diagnosis and localization of ulnar neuropathy at the elbow.
Elbow	von Schroeder & Scheker (2003)	Cadaver study	11 Canadian specimens (8 females, 3 male) with an average age of 74	The arcade of Struthers is an anatomic variation that is better defined as a canal through which the ulnar nerve travels from the anterior to the posterior compartments of the arm.	The arcade of Struthers is considered to be a potential site of entrapment or compression of the ulnar nerve	Comprehensive knowledge of the canal is necessary for treating the various causes of neuropathies and other conditions of the ulnar nerve
Elbow	De Rudder <i>et al.</i> (2020)	Surgical intervention; case report	48-year-old symptomatic male from The Netherlands	A muscular arcade of Struthers	The arcade of Struthers can cause compression of the ulnar nerve proximal to the elbow	As there is a high prevalence of the arcade of Struthers in some cadaver studies, it might need to be considered a possible cause of cubital tunnel syndrome
Wrist	al-Ostain & Dierksen (1992)	Surgical exploration; case report	38-year-old Canadian male right hand	Duplication of the tendon of flexor carpi ulnaris with the splitting of the ulnar nerve. The ulnar part of the tendon was inserted into the pisiform bone and the radial part slipped into the proximal phalanx of the ring finger.	An ulnar nerve compression can be caused by anatomic variations in the flexor carpi ulnaris muscle.	Clinically, there are multiple reported anatomical variations of flexor carpi ulnaris causing ulnar nerve compression.
Wrist	Bozkurt <i>et al.</i> (2005)	Cadaver study	37 hands and forearms from 19 adults (14 male, 5 female)	A fibrous arch that uses the pisiform and the hook of the hamate (incidence: 56.7 %). An anomalous muscle in the Guyon's canal (incidence: 16.2 %)	The accessory muscles coursing through Guyon's canal and the fibrous arch overlying the deep motor branch of the ulnar nerve and similar normal anatomic variants may predispose to ulnar entrapment.	The clinical implication of this fibrous arch, contributing to the ulnar nerve entrapment, is usually an indirect impact on the ulnar nerve. This type of compression usually originates from the existence of extra structures in the canal (i.e., ganglia or accessory muscles).

Region	Author (year)	Study type	Sample	Variation	Differential diagnosis	Clinical interpretation
Upper limb	Wartsch & Melvin (1982)	Literature review	Not reported	Median nerve entrapment can occur at multiple sites along this nerve; ligament of Struthers, pronator teres syndrome, and carpal tunnel syndrome.	- A rare point of median nerve entrapment could be the ligament of Struthers - Entrapment of the median palmar cutaneous nerve by an anomalous palmaris longus muscle may give pain and numbness in the thenar area as a differential diagnosis for carpal tunnel syndrome - Pronator teres syndrome: besides the muscle, an aberrant fibrous component of the flexor carpi radialis from the ulna could trap the median nerve at this level	As a result of frequently occurring anatomic variations of the median nerve, failure to recognize these could lead to diagnostic confusion. To successfully diagnose and treat median nerve entrapment syndromes a knowledge of possible involved sites as well as detailed knowledge of median nerve anatomy is important, as an appropriate treatment of the entrapment requires an accurate identification.
Forearm	Wan <i>et al.</i> (2010)	Case report	85-year-old Korean male	A variation where the median nerve split into two divisions in the proximal forearm and continued into a single cord in the distal forearm before entering the carpal tunnel. With a larger medial division crossed over by an aberrant muscular slip (flexor digitorum superficialis) may have caused entrapment syndrome as several muscular and cutaneous branches originated and passed through the Pronator Teres muscle and continued distally where it split the median nerve.	The aberrant muscular part over the medial division of the split median nerve might lead to entrapment syndrome. This entrapment syndrome (which should be distinguished from carpal tunnel syndrome) might influence the sensation of the thenar eminence and the movement of the Flexor digitorum superficialis muscle.	This variation may affect the diagnosis and treatment of any neuropathy of the median nerve.
Forearm	Hızay & Sarikaya (2011)	Case report	50-year-old cadaver from Turkey	A splitting of the ulnar nerve by the ulnar artery. The ulnar artery passed through the Pronator Teres muscle and continued distally where it split the median nerve.	This variation could irritate the median nerve from the pulsation of the ulnar artery	This variation should therefore not be overlooked in diagnostic procedures; however, the incidence of a split median nerve is not that common.
Forearm	Peperkamp <i>et al.</i> (2022)	Literature review	62 studies	35 venous, 16 vascular causes, and 4 cases with nerve involvement were found. Only 1 osseous and 18 combined anomalies caused median nerve compression. In 18 cases, the anomaly was found in the proximal forearm.	Persistent or recurrent carpal tunnel syndrome, unilateral symptoms, the presence of a palpable mass, the manifestation of age, and pain in the forearm or upper arm	The presence of an anatomical anomaly may be ruled out before surgery. Complete resection is not always necessary.
Forearm	Markeson <i>et al.</i> (2012)	Case report of diagnostic and therapeutic importance	Symptomatic 37-year-old from the United Kingdom	A palmaris longus variant with a central muscle belly and both distal and proximal tendinous insertions causing median nerve compression in a dynamic process at the mid-forearm level.	Entrapment of the median nerve by a palmaris longus muscle variant. As it is thought to be caused by direct compression of the median nerve used by within, but occasionally immediately proximal to, the carpal tunnel. This might be a potential differential diagnosis to the cause of carpal tunnel syndrome	This case report helps our understanding of nerve entrapment phenomena in the forearm and presents another clinical presentation of the incredibly variable palmaris longus muscle.
Forearm	Stavros <i>et al.</i> (2016)	Neuromuscular ultrasound study	Symptomatic CTS 47 years old man from South Korea	Neuromuscular ultrasound of the median nerve on the symptomatic side revealed penetration of the nerve by a persistent median artery and vein in the mid-forearm.	The neuromuscular ultrasound found a structural cause of the symptoms, namely an unusual anatomical variation proximal to the carpal tunnel, which resulted in a carpal tunnel syndrome mimic.	It is important to consider anatomical variation involving the median nerve in the differential diagnosis of carpal tunnel syndrome.
Forearm	Hansen <i>et al.</i> (2020)	Case report: median nerve compression	An asymptomatic 24-year-old male from Canada	A hypertrophied palmaris longus muscle used swelling on the forearm with symptoms of median nerve compression.	When symptoms of median nerve compression are present variations of the palmaris longus muscle should be considered in the differential diagnosis.	Awareness regarding unusual variations of the palmaris longus muscle is important and therefore the use of radiological investigations is important to establish a diagnosis.
Elbow and forearm	Olevnik <i>et al.</i> (2018)	Case study	50 upper limbs (26 left and 24 right) from adult cadavers from Poland	The median nerve passed between the heads of the pronator teres muscle (incidence 74%) or under the muscle (incidence 26%). In the majority of cases, it provided two motor branches (incidence 66%). Variations were divided into two parts. Firstly, variation in the pronator teres muscle morphology and its association with median nerve morphology and forearm length. Secondly variations in the number of muscular branches who supply the pronator teres muscle.	Pronator teres syndrome is often overlooked and mistaken for the more frequent carpal tunnel syndrome	The knowledge that the cubital region is a potential site of proximal median nerve entrapment should be taken into account to better differentiate pronator teres syndrome from carpal tunnel syndrome.
The connection between Median and Musculocutaneous nerve						
Upper arm	Chryssikos <i>et al.</i> (2020)	Case report	An 89-year-old male of Greek origin	A common teating branch between the median and the musculocutaneous nerve before the musculocutaneous nerve perforated the coracobrachialis muscle.	Entrapment of this variant of the musculocutaneous nerve may cause clinical findings similar to those of carpal tunnel syndrome.	Connections between the median and the musculocutaneous nerve have a significant clinical impact
Brachial Plexus						
Axilla	Smith Jr. & Cummings (2006)	Case report	An 81-year-old male from the United States of America	Bilateral axonal bands of the latissimus dorsi muscle passed anterior to the axillary neurovascular bundle and blended distally with the fascia of the coracobrachialis. Otherwise known as the axillary arch or "Arch of Langer".	The existence of an axillary arch should be considered in patients with signs and symptoms consistent with upper limb neurovascular compromise similar to thoracic outlet syndrome	The inclusion of this variant in the differential diagnostic process might assist physical therapists in the management of patients with signs and symptoms consistent with thoracic outlet syndrome
Axilla	Troupis <i>et al.</i> (2015)	Case report	Greek Male cadaver	Bilateral anatomic variations involving the brachial plexus and brachial artery system were encountered. A superficial brachial artery is a brachial artery that runs above the median nerve level. A communicating branch between the musculocutaneous and median nerve before the nerves entering at the coracobrachialis.	A superficial brachial artery predisposes to various neuropathies due to nerve compression.	Clinicians should be alert for these anatomic variations. If encountered, they might need to modify their therapeutic or surgical interventions to provide an effective treatment

Anagnostopoulou, 1998; Ghosh *et al.*, 2022; Passey *et al.*, 2022), with incidences ranging between 10-54 % (Guerriguttenberg & Ingolotti, 2009). Their common origin has previously been proposed as an explanation for the frequent presence of communicating branches (Prasado Rao & Chaudhary, 2000). Further, neural communications and variations tend to be observed more often between nerves in the same plane such as the musculocutaneous and median nerves, in contrast to the rare interconnections between the radial and ulnar nerves (Natsis *et al.*, 2018). Any injury proximal to the connecting branch may cause an unexpected presentation of symptoms such as weakness of the forearm flexors and thenar muscles or even present as a double nerve injury (Sthapak *et al.*, 2018). A nerve lesion of the communicating branch itself may show confusing symptoms making differential diagnosis challenging. Although, to the knowledge of the authors, there are no electrophysiological reports investigating the clinical presentation of lesions to the connecting branch itself, El Falougy *et al.* (2013) suggested an injury could cause compound musculocutaneous and median nerve neuropathy. When the connection is present distally to the musculocutaneous nerve penetrating point through the coracobrachialis muscle, musculocutaneous nerve compression at the level of the coracobrachialis muscle may present itself along with median nerve compression at the forearm, e.g. a pronator teres syndrome. Case reports identified a motor innervation of the flexor compartment and sensory innervation of the lateral part of the forearm by the median nerve, when the musculocutaneous nerve is absent (Moore *et al.*, 2020). In this case, a solitary neuropathy of the median nerve may be confused with a double nerve injury.

The most frequently mentioned connections between the ulnar nerve and the median nerve are the Martin-Gruber anastomosis and the Riche-Cannieu anastomosis. The former is one of the most common neural connections reported to occur between 7 % and 40 % (Lee *et al.*, 2005; Diz-Diaz *et al.*, 2019). A meta-analysis of 41 studies estimated its prevalence at 19.5 % (Roy *et al.*, 2016). There is some ambiguity about whether this connection pertains to motor fibres, sensory fibres, or both. Diz-Diaz *et al.* (2019) found that connections were composed of both sensory and motor fibres in almost a third of the dissected specimen after immunohistochemical staining. This connection might be clinically relevant as it could complicate the diagnosis of carpal tunnel syndrome (Simonetti & Karup, 2000), cubital tunnel syndrome, and peripheral lesions (Smith *et al.*, 2019). For example, if a Martin-Gruber anastomosis is present, a patient might present symptoms of carpal tunnel syndrome but the Tinel's and Phalen's tests might be both negative, as a result of ulnar compression at the elbow (Roy *et al.*, 2016). This is a perfect example of confusing symptoms or signs,

where the knowledge of the Martin-Gruber anastomosis is crucial for an accurate diagnosis.

According to a meta-analysis in more than 10.000 upper limbs the Riche-Cannieu anastomosis has a pooled prevalence of 55 % (Roy *et al.*, 2016). It is a connection between the deep branch of the ulnar nerve and the recurrent branch of the median nerve where both sensory and motor fibres could be involved (Smith *et al.*, 2019). The clinical presentation may show itself in a way that the hand is completely innervated by the ulnar nerve, or that the hand has motor fibres exclusively from the ulnar nerve or that it has normal median-innervated muscles that are partially innervated by the ulnar nerve (Falconer & Spinner, 1985; Smith *et al.*, 2019). These differences create different innervation patterns that might be relevant for diagnosis. For example, abnormalities of the first dorsal interosseous muscle during EMG examination may reflect a median nerve problem instead of an ulnar lesion (Wertsch & Melvin, 1982). On the other hand, a positive Tinel's sign and/or Phalen's test may present itself with paradoxical preservation of thenar muscle function (Refaeian *et al.*, 2001; Tamagawa *et al.*, 2004). Therefore, we suggest that the wide sensitivity and specificity ranges reported in the literature for the Phalen's test in the clinical diagnosis of carpal tunnel syndrome (Alanazy *et al.*, 2021), may be partly explained by the presence of interconnections between the median and ulnar nerves.

Differential diagnosis. The anatomical variations that have been related to entrapment or compression neuropathies are arguably equally relevant to clinicians. Musculoskeletal diagnosis is frequently guiding in the management of nerve neuropathies including the choice of the appropriate treatment (Heick & Lazaro, 2022). Although conservative treatment for compression neuropathies often is the first choice of treatment, especially in mild or moderate cases, a surgical release may be preferred over conservative treatment when the entrapment is caused by a specific anatomical structure (Freund *et al.*, 2021). Moreover, knowledge of anatomical entrapment or compression sites including variations is indispensable as nerve entrapment may occur at multiple sites along its course resulting in superimposed compressions (Upton & McComas, 1973). It has been hypothesized that non-symptomatic impairment of axoplasmic flow at more than one site along a nerve might summate to cause symptomatic neuropathy (Upton & McComas, 1973). Variations causing entrapment syndromes are most often related to the median or ulnar nerves. Muscular, vascular, or combined anomalies in the (fore)arm, when overlooked, may be mistaken for carpal tunnel syndrome or compression at Guyon's canal or misdiagnosed as pronator teres or cubital tunnel syndrome (Peperkamp *et al.*, 2022).

Pronator teres syndrome is the compression of the median nerve by the pronator teres muscle. It is a rather rare condition. Pronator teres syndrome might be more prevalent in men compared to women (Mahsa *et al.*, 2016). An additional fibrous brand between the two heads of the pronator teres muscle may cause pronator teres syndrome (Dididze *et al.*, 2022). As its clinical presentation is similar to carpal tunnel syndrome, it is often misdiagnosed as the latter (Mahsa *et al.*, 2016). The incidence of the median nerve passing between the two heads of the pronator teres muscle is between 74 % and 82 % (Olewnik *et al.*, 2018; Dididze *et al.*, 2022). Muscle hypertrophy caused by repetitive pronation motions may entrap or compress the median nerve, especially when an additional fibrous band is present (Stavros *et al.*, 2016; Olewnik *et al.*, 2018; Dididze *et al.*, 2022). Ultrasound might have been suggested as the best tool to diagnose pronator teres syndrome due to its dynamic character and proven positive correlation between the cross-sectional area of the median nerve, severity, and duration of the symptoms (Mahsa *et al.*, 2016). However, pronator teres syndrome differs from carpal tunnel syndrome as the former also involves the deep flexors of the forearm causing weakness of the first and second fingers. In carpal tunnel syndrome, the sensory innervation of the thenar eminence is spared, as the palmar cutaneous branches leave the median nerve proximal to the carpal tunnel and nocturnal paraesthesia is more a symptom of carpal tunnel syndrome (Nebot-Cegarra *et al.*, 1991).

Median nerve entrapment can also occur at multiple sites along its course by muscular variations. For example, variations of the palmaris longus muscle causing entrapment of the medial palmar cutaneous nerve have been reported in three articles, even though literature suggests that compression of the median nerve at the level of the wrist caused by an anomalous muscle is rare (Guclu *et al.*, 2018). An accessory palmaris longus muscle may cause dynamic median nerve compression at the wrist (Wertsch & Melvin, 1982; Markeson *et al.*, 2012; Guclu *et al.*, 2018; Hashem *et al.*, 2020). As this variation might provoke pain and/or numbness in the thenar region, it is a differential diagnosis for carpal tunnel syndrome (Wertsch & Melvin, 1982). In other literature on palmaris longus variations, it was found that these variations might cause symptoms or even painful syndromes such as carpal tunnel syndrome or Guyon's syndrome (Ioannis *et al.*, 2015). Knowledge of this variation is necessary, as the recommended treatment for entrapment by a palmaris longus variation, is the surgical removal of this muscle (Ioannis *et al.*, 2015). Radiological examinations (e.g. ultrasound or magnetic resonance imaging) may therefore be indicated during differential diagnosis of median nerve compression (Guclu *et al.*, 2018). However, a high incidence rate of a variation might be indicative of

further exploration during the differential diagnostic process, especially when provocative tests of the wrist do not provoke or amplify the known symptoms.

Ulnar neuropathy at the elbow is the second most common entrapment neuropathy in the upper limb, after carpal tunnel syndrome (Doughty & Bowley, 2019). Ulnar nerve compression can be divided into static compression and dynamic compression (Cambon-Binder, 2021). An example of static compression and a possible cause of ulnar nerve entrapment is the arcade of Struthers. It is a fibrous canal where at the proximal end of this canal, at the intermuscular septum, a clinically relevant site of entrapment or compression can be found. An incidence of 60 % to 70 % of cases has been reported in dissection studies (von Schroeder & Scheker, 2003). As the arcade of Struthers may cause symptoms of ulnar neuropathy (De Ruiter *et al.*, 2020), mimicking cubital syndrome, its existence is of clinical interest. Further, compression of the ulnar nerve by the flexor carpi ulnaris muscle may be confused with cubital tunnel syndrome or even Guyon's syndrome (Wang & Ng, 2021).

The incidence of Wartenberg's syndrome, the entrapment or compression of the superficial radial nerve, an exclusively sensory nerve, is not known (Kuschner & Berihun, 2021). The radial nerve descends in the cubital fossa region, splitting into the posterior interosseous nerve (the motor branch) and the superficial nerve (the sensory branch). The sensory branch runs superficial to the supinator muscle, along the ulnar edge, and deep to the brachioradialis muscle. After that, it becomes subcutaneous between the brachioradialis muscle and the tendon of the extensor carpi radialis longus muscle (Kuschner & Berihun, 2021). This nerve has been reported to be the most vulnerable to compression where it travels from deep to superficial, at the edge of the brachioradialis muscle (Kuschner & Berihun, 2021). However, when the superficial branch of the radial nerve pierces through the brachioradialis muscle this variant course may predispose the nerve to compression neuropathy (Tryfonidis *et al.*, 2004). Lanzetta & Foucher (1993) reported 52 cases of Wartenberg's syndrome, of which 50 % were diagnosed as de Quervain's tendinitis, and concluded: "is probably too often misdiagnosed as de Quervain's disease or, in the presence of this condition, it is not diagnosed at all".

Undeniably a detailed knowledge of anatomical variations is primordial in clinical practice (Kubwimana *et al.*, 2022). Cadaver dissection is a valuable tool to understand the range of normal anatomy including variations (Alraddadi, 2021; Willan & Humpherson, 1999). However, there is a major need for in vivo diagnostic studies on symptomatic subjects to understand the causality between nerve variations in the upper limb and non-classical signs and symptoms. The current evidence on the importance of anatomical

variations for clinical decision making is primarily based on cadaver dissection or surgical exploration. As a result, the clinical presentation of most nerve variations remains undetermined. It is hypothesized that nerve variations contribute to the development of compression neuropathies. However, to the knowledge of the authors, there is little proof how anatomical variations may contribute qualitatively to the development of compression neuropathies. No reports exist on the complimentary contribution of anatomical structures to multiple site compression neuropathies. Emerging imaging methods such as functional magnetic resonance neurography (fMRN) are supposed to partially close this current research gap. According to Bergmeister *et al.* (2018) fMRN has the potential to improve diagnostic accuracy and therapeutic decision making. For example, diffusion-weighted imaging (DWI) or diffusion tensor imaging (DTI) can provide valuable information about the functional status of a nerve based on axonal flow integrity (Noguerol *et al.*, 2019). As such, DWI and DTI are able to detect the fibre integrity of a peripheral nerve segment. However, as this novel technique has not been tested directly in a clinical setting for the identification of motor and sensory nerve fascicles (Xianyu *et al.*, 2016), its potential for determining fibre composition remains undetermined. Therefore, the functional implication of an injury to a nerve, for example to the interconnection between the median and ulnar nerve, remains speculative and makes clinical decision challenging.

Study Limitations. The screening and data extraction of the studies were conducted by one person (EW). Due to the scope of this review, the number of included articles is rather low, as research investigating the influence of anatomic variation on the diagnostic process is scarce. Many studies on anatomical variation are case reports reporting the discovery of an anatomical variation. As a consequence, the clinical importance of variations based on cadaver dissections is not always clear and may therefore remain speculative.

CONCLUSION

Anatomical nerve variations in the upper limb may alter the clinical diagnosis. Variations causing a different innervation pattern, such as connections between nerves or the absence of a nerve, may show atypical signs and symptoms during a clinical examination. At the same time, compression neuropathies may also be caused by anomalous anatomical structures. Common variations should be acknowledged in clinical diagnosis and ruled out before intervention.

SCAFOGLIERI, A.; WYNANT, E.; HÉRÉUS, S.; VAN DEN BROECK, J. & CATTRYSSSE, E. Las variaciones nerviosas de los miembros superiores pueden alterar el diagnóstico clínico: Una revisión del alcance. *Int. J. Morphol.*, 41(2):555-568, 2023.

RESUMEN: Las variaciones nerviosas del miembro superior pueden estar relacionadas con la ausencia de un nervio, una interconexión entre dos nervios o un curso variante. El objetivo de esta revisión fue examinar la literatura existente sobre las variaciones de los nervios de los miembros superiores que pueden alterar el proceso de diagnóstico neurológico. Se realizó una revisión de alcance siguiendo las pautas de PRISMA para revisiones de alcance. Inicialmente, se identificaron 1331 artículos mediante la búsqueda en Pubmed y Web of Science hasta el 22 de octubre de 2022. Después de la selección, la lectura y la búsqueda adicional, se incluyeron 50 artículos en esta revisión. Las variaciones se dividieron en dos categorías: 1) variaciones que causan un patrón de inervación diferente que involucra fibras sensoriales, motoras o de ambos tipos, y 2) variaciones que causan o están relacionadas con síndromes de compresión. Dos tercios de los artículos incluidos eran estudios de cadáveres. Nueve artículos fueron estudios de diagnóstico en individuos sintomáticos o sanos que involucraron imágenes médicas y/o cirugía. Las variaciones nerviosas que pueden causar un patrón de inervación diferente se refieren con mayor frecuencia a su interconexión. La conexión entre el nervio mediano y musculocutáneo en el miembro superior y la conexión entre el nervio mediano y ulnar en el antebrazo (Martin-Gruber) o la mano (Riche-Cannieu) puede estar presente en la mitad de la población. La lesión de estas conexiones puede causar neuropatías periféricas compuestas como resultado de patrones de ramificación variantes sensitivos y motores. Se informaron anomalías musculares, vasculares o combinadas en el antebrazo como causas de neuropatías por atrapamiento. Estas variaciones nerviosas pueden imitar los síndromes de atrapamiento clásicos, como el síndrome del túnel carpiano o la compresión en el canal ulnar. El conocimiento de las variaciones nerviosas frecuentes en el brazo puede ser importante durante el proceso de diagnóstico y examen. Los patrones de inervación variantes pueden explicar los signos y/o síntomas clínicos no clásicos durante las pruebas de provocación. Los síndromes clásicos de compresión nerviosa en el brazo pueden justificar el diagnóstico diferencial, especialmente en el caso de síntomas persistentes o recurrentes.

PALABRAS CLAVE: Nervio; Variación anatómica; Miembro superior; Diagnóstico; Patología.

REFERENCES

- Al-Qattan, M. M. & Duerksen, F. A variant of flexor carpi ulnaris causing ulnar nerve compression. *J. Anat.*, 180(Pt. 1):189-90, 1992.
- Alanazy, M. H.; Albulaihe, H.; Alhumayyd, Z.; Albarrak, A. M. & Abuzinadah, A. R. A timed Phalen's test predicts abnormal electrophysiology in carpal tunnel syndrome. *Brain Behav.*, 11(4):e02056, 2021.
- Alraddadi, A. Literature review of anatomical variations. clinical significance, identification approach, and teaching strategies. *Cureus*, 13(4):e14451, 2021.

- Atoni, A. D. & Oyinbo, C. A. Anatomic variation of the median nerve associated with an anomalous muscle of the forearm. *Folia Med. (Plovdiv)*, 59(1):106-109, 2017.
- Beheiry, E. E. Anatomical variations of the median nerve distribution and communication in the arm. *Folia Morphol. (Warsz.)*, 63(3):313-318, 2004.
- Bergmeister, K. D.; Schönle, P.; Böcker, A. H.; Kronlage, M.; Godel, T.; Daeschler, S.; Bendszus, M.; Kneser, U.; Harhaus, L. & Schwarz, D. Improved diagnostics and therapeutic decision making in traumatic peripheral nerve lesions using MR-neurography. *Handchir. Mikrochir. Plast. Chir.*, 50(4):232-240, 2018.
- Bozkurt, M. C.; Tagil, S. M.; Ozcakar, L.; Ersoy, M. & Tekdemir, I. Anatomical variations as potential risk factors for ulnar tunnel syndrome: a cadaveric study. *Clin. Anat.*, 18(4):274-80, 2005.
- Butz, J. J.; Shiwlochan, D. G.; Brown, K. C.; Prasad, A. M.; Murlimanju, B. V. & Viswanath, S. Bilateral variations of brachial plexus involving the median nerve and lateral cord: An anatomical case study with clinical implications. *Australas. Med. J.*, 7(5):227-31, 2014.
- Cambon-Binder, A. Ulnar neuropathy at the elbow. *Orthop. Traumatol. Surg. Res.*, 107(1S):102754, 2021.
- Campbell, W. W.; Pridgeon, R. M.; Riaz, G.; Astruc, J. & Sahni, K. S. Variations in anatomy of the ulnar nerve at the cubital tunnel: pitfalls in the diagnosis of ulnar neuropathy at the elbow. *Muscle Nerve*, 14(8):733-8, 1991.
- Chrysikos, D.; Athanasopoulos, A.; Georgakopoulos, P.; Antonopoulos, I.; Samolis, A. & Troupis, T. Anatomical variation of a communicating branch between the musculocutaneous and the median nerve: A case report. *Acta Med. Acad.*, 49(1):71-4, 2020.
- De Ruiter, G. C. W.; De Jonge, J. G. H.; Vlak, M. H. M. & van Loon-Felter, A. E. Ulnar neuropathy caused by muscular arcade of Struthers. *World Neurosurg.*, 142:128-30, 2020.
- Dididze, M.; Tafti, D. & Sherman, A. I. *Pronator Teres Syndrome*. In: StatPearls. Internet. Treasure Island (FL), StatPearls Publishing; 2022.
- Diz-Díaz, J.; Gómez-Muñoz, E.; Sañudo, J.; Marañillo, E.; Pascual-Font, A. & Vazquez, T. Which is the function of a martin-gruber connection? *Clin. Anat.*, 32(4):501-8, 2019.
- Doughty, C. T. & Bowley, M. P. Entrapment neuropathies of the upper extremity. *Med. Clin. North Am.*, 103(2):357-70, 2019.
- El Falougy, H.; Selmeçiova, P.; Kubikova, E.; Stenova, J. & Haviarova, Z. The variable communicating branches between musculocutaneous and median nerves: a morphological study with clinical implications. *Bratisl. Lek. Listy*, 114(5):290-4, 2013.
- Falconer, D. & Spinner, M. Anatomic variations in the motor and sensory supply of the thumb. *Clin. Orthop. Relat. Res.*, (195):83-96, 1985.
- Freund, G.; Dafotakis, M.; Bahm, J. & Beier, J. P. Treatment of peripheral nerve compression syndromes of the upper extremities: A systematic review. *Z. Orthop. Unfall*, 2021. DOI: <https://www.doi.org/10.1055/a-1498-3197>
- Ghosh, B.; Dilkash, M. N. A.; Prasad, S. & Sinha, S. K. Anatomical variation of median nerve: cadaveric study in brachial plexus. *Anat. Cell. Biol.*, 55(2):130-4, 2022.
- Guclu, D.; Arican, M. & Unlu, E. N. Median nerve entrapment due to accessory palmaris longus muscle: MRI and sonography findings. *BMJ Case Rep.*, 2018:bcr2018224852, 2018.
- Guerri-Guttenberg, R. A. & Ingolotti, M. Classifying musculocutaneous nerve variations. *Clin. Anat.*, 22(6):671-83, 2009.
- Gümüşburun, E. & Adigüzel, E. A variation of the brachial plexus characterized by the absence of the musculocutaneous nerve: a case report. *Surg. Radiol. Anat.*, 22(1):63-65, 2000.
- Guru, A.; Kumar, N.; Shanthakumar, S. R.; Patil, J.; Badagabettu, S. N.; Padur, A. A. & Nelluri, V. M. Anatomical study of the ulnar nerve variations at high humeral level and their possible clinical and diagnostic implications. *Anat. Res. Int.*, 2015:378063, 2015.
- Hashem, M.; Alatassi, R.; Narinder, K. & Emran, F. Hypertrophied reversed palmaris longus muscle (pseudotumor) of the forearm causing median nerve compression: a case report. *J. Med. Case Rep.*, 14(1):60, 2020.
- Haviarova, Z.; El Falougy, H.; Killingerova, A. & Matejcik, V. Variation of the median nerve course and its clinical importance. *Biomed. Pap. Med. Fac. Univ. Palacky Olomouc Czech Repub.*, 153(4):303-6, 2009.
- Hefny, M.; Sallam, A.; Abdellatif, M.; Okasha, S. & Orabi, M. Electrophysiological evaluation and clinical implication of Martin-Gruber anastomosis in healthy subjects. *J. Hand Surg. Asian Pac. Vol.*, 25(1):87-94, 2020.
- Heick, J. & Lazaro, R. T. (Eds.). *Goodman and Snyder's Differential Diagnosis for Physical Therapists. Screening for Referral*. 7th ed. Amsterdam, Elsevier, 2022. pp.816.
- Hemmi, S.; Kurokawa, K.; Nagai, T.; Okamoto, T.; Asano, A.; Murakami, T.; Mihara, M. & Sunada, Y. Anatomical variations of the superficial branch of the radial nerve and the dorsal branch of the ulnar nerve: A detailed electrophysiological study. *Muscle Nerve*, 63(6):913-8, 2021.
- Herma, T.; Baca, V.; Yershov, D. & Kachlik, D. A case of a duplicated superficial branch of radial nerve and a two-bellied brachioradialis muscle presenting a potential entrapment syndrome. *Surg. Radiol. Anat.*, 39(4):451-4, 2017.
- Hizay, A. & Sarikcioglu, L. A unique case with splitting of the median nerve by the ulnar artery. *Rom. J. Morphol. Embryol.*, 52(2):723-4, 2011.
- Hur, M. S. Variations of lumbrical muscle innervation patterns in the hand, focusing on the dual innervation of the third lumbrical muscle. *Muscle Nerve*, 55(2):160-5, 2017.
- Ioannis, D.; Anastasios, K.; Konstantinos, N.; Lazaros, K. & Georgios, N. Palmaris longus muscle's prevalence in different nations and interesting anatomical variations: Review of the literature. *J. Clin. Med. Res.*, 7(11):825-30, 2015.
- Johnson, E. O.; Vekris, M.; Demesticha, T. & Soucacos, P. N. Neuroanatomy of the brachial plexus: normal and variant anatomy of its formation. *Surg. Radiol. Anat.*, 32(3):291-7, 2010.
- Krishnamurthy, A.; Nayak, S. R.; Prabhu, L. V.; Hegde, R. P.; Surendran, S.; Kumar, M. & Pai, M. M. The branching pattern and communications of the musculocutaneous nerve. *J. Hand Surg. Eur. Vol.*, 32(5):560-2, 2007.
- Kubwimana, O.; Ndata, A.; Ivang, A.; Ndahimana, P.; Nzayisenga, A.; Byiringiro, J. C. & Gashegu, J. Musculocutaneous and median nerve branching: anatomical variations. Case Series from UR clinical anatomy and literature review. *Afr. Health Sci.*, 22(1):263-8, 2022.
- Kuschner, S. H. & Berihun, H. Robert Wartenberg syndrome and sign: A review article. *Open Orthop. J.*, 15:13-6, 2021.
- Lanzetta, M. & Foucher, G. Entrapment of the superficial branch of the radial nerve (Wartenberg's syndrome). A report of 52 cases. *Int. Orthop.*, 17(6):342-5, 1993.
- Lee, K. S.; Oh, C. S.; Chung, I. H. & Sunwoo, I. N. An anatomic study of the Martin-Gruber anastomosis: electrodiagnostic implications. *Muscle Nerve.*, 31(1):95-7, 2005.
- Lee, S. H.; Jeon, J. Y. & Yoon, S. P. A combined variation of the musculocutaneous nerve associated with a supernumerary head of the biceps brachii muscle. *Folia Morphol. (Warsz.)*, 73(3):366-9, 2014.
- Leis, A. A.; Stetkarova, I. & Wells, K. J. Martin-Gruber anastomosis with an anomalous superficial radial innervation to ulnar dorsum of hand: a pitfall when common variants coexist. *Muscle Nerve*, 41(3):313-7, 2010.
- Madhavi, C. & Holla, S. J. Dual sensory innervation of the dorsum of the thumb. *Clin. Anat.*, 16(4):344-5, 2003.
- Mahan, M. A. & Spinner, R. J. *Clinical Importance of Anatomic Variation of the Nerves of the Upper Extremity*. In: Tubbs, R. S.; Rizk, E. B.; Shoja, M.; Loukas, M.; Barbaro, N. & Spinner, R. J. (Eds.). *Nerves and Nerve Injuries Vol. 1: History, Embryology, Anatomy, Imaging, and Diagnostics*. Amsterdam, Elsevier, 2015. pp.589-605.
- Mahsa, A.; Hollisaz, M.; Aghdam, A. & Khatibiaghda, A. The prevalence of pronator teres among patients with carpal tunnel syndrome: cross-sectional study. *Int. J. Biomed. Sci.*, 12(3):89-94, 2016.
- Markeson, D.; Basu, I. & Kulkarni, M. K. The dual tendon palmaris longus variant causing dynamic median nerve compression in the forearm. *J. Plast. Reconstr. Aesthet. Surg.*, 65(8):e220-2, 2012.

- Moore, K.; Prasad, A. M. & Nayak, B. S. Absence of the musculocutaneous nerve and associated compensation by the median nerve. *Kathmandu Univ. Med. J. (KUMJ)*, 18(71):313-5, 2020.
- Natsis, K.; Giannakopoulou, A.; Piagkou, M.; Lazaridis, N.; Tegos, T. & Colonna, M. R. Connections between radial and ulnar nerve at high humeral level in cadavers: incidence, topography, and literature review. *Surg. Radiol. Anat.*, 40(3):313-22, 2018.
- Nebot-Cegarra, J.; Perez-Berrueto, J. & Reina de la Torre, F. Variations of the pronator teres muscle: predispositional role to median nerve entrapment. *Arch. Anat. Histol. Embryol.*, 74:35-45, 1991.
- Niitsu, M.; Kokubo, N. & Nojima, S. Variations of the ulnar nerve in Guyon's canal: in vivo demonstration using ultrasound and 3 T MRI. *Acta Radiol.*, 51(8):939-46, 2010.
- Noguerol, T. M.; Barousse, R.; Gómez Cabrera, M.; Socolovsky, M.; Bencardino, J. T. & Luna, A. Functional MR Neurography in Evaluation of Peripheral Nerve Trauma and Postsurgical Assessment. *Radiographics*, 39(2):427-46, 2019.
- Olewnik, L.; Podgórski, M.; Polguj, M.; Wysiadecki, G. & Topol, M. Anatomical variations of the pronator teres muscle in a Central European population and its clinical significance. *Anat. Sci. Int.*, 93(2):299-306, 2018.
- Ongeti, K.; Pulei, A.; Ogeng'o, J. & Saidi, H. Unusual formation of the median nerve associated with the third head of biceps brachii. *Clin. Anat.*, 25(8):961-2, 2012.
- Ouzzani, M.; Hammady, H.; Fedorowicz, Z. & Elmagarmid, A. Rayyan—a web and mobile app for systematic reviews. *Syst. Rev.*, 5:210, 2016.
- Oztürk, N. C.; Uzmansel, D. & Oztürk, H. An unreported pattern of musculocutaneous and median nerve communication with multiple variations of biceps brachii: a case report. *Surg. Radiol. Anat.*, 32(9):887-90, 2010.
- Passey, J.; Rabbani, P.; Razdan, S. K.; Kumar, S. & Kumar, A. Variations of median nerve formation in North Indian population. *Cureus*, 14(1):e20890, 2022.
- Peperkamp, K.; Natroshvili, T.; Malyar, M. A.; Heine, E. P. & Walbeehm, E. T. Anatomic variations and malformations as rare causes of median nerve compression in adults: A narrative review. *Ann. Plast. Surg.*, 88(2):237-43, 2022.
- Polatsch, D. B.; Melone Jr, C. P.; Beldner, S. & Incorvaia, A. Ulnar nerve anatomy. *Hand Clin.*, 23(3):283-9, 2007.
- Rao, P. V. P. & Chaudhary, S. C. Communication of the musculocutaneous nerve with the median nerve. *East Afr. Med. J.*, 77(9):498-503, 2000.
- Refaeian, M.; King, J. C.; Dumitru, D. & Cuetter, A. C. Carpal tunnel syndrome and the Riche-Cannieu anastomosis: electrophysiologic findings. *Electromyogr. Clin. Neurophysiol.*, 41(6):377-82, 2001.
- Rogers, M. R.; Bergfield, T. G. & Aulicino, P. L. A neural loop of the deep motor branch of the ulnar nerve: an anatomic study. *J. Hand Surg. Am.*, 16(2):269-271, 1991.
- Roy, J.; Henry, B. M.; Pekala, P. A.; Vikse, J.; Saganiak, K.; Walocha, J. A. & Tomaszewski, K. A. Median and ulnar nerve anastomoses in the upper limb: A meta-analysis. *Muscle Nerve.*, 54(1):36-47, 2016.
- Saluja, S.; Das, S. S.; Kumar, D. & Goswami, P. Bilateral three-headed biceps brachii muscle and its clinical implications. *Int. J. Appl. Basic Med. Res.*, 7(4):266-8, 2017.
- Simonetti, S. & Krarup, C. Unusual ulnar sensory innervation and Martin-Gruber anastomosis in a patient with a carpal tunnel syndrome. *J. Neurol.*, 247(2):141-2, 2000.
- Smith Jr., R. A. & Cummings, J. P. The axillary arch: anatomy and suggested clinical manifestations. *J. Orthop. Sports Phys. Ther.*, 36(6):425-429, 2006.
- Smith, J. L.; Siddiqui, S. A. & Ebraheim, N. A. Comprehensive summary of anastomoses between the median and ulnar nerves in the forearm and hand. *J. Hand Microsurg.*, 11(1):1-5, 2019.
- Solia, E.; Panagouli, E.; Angelis, S.; Apostolopoulos, A. P.; Piagkou, M. & Filippou, D. K. Variations of ulnar nerve in the forearm and hand: A review of the literature and clinical significance. *J. Long Term Eff. Med. Implants*, 32(1):45-59, 2022.
- Soubeyrand, M.; Melhem, R.; Protais, M.; Artuso, M. & Crézé, M. Anatomy of the median nerve and its clinical applications. *Hand Surg; Rehabil.*, 39(1):2-18, 2020.
- Stavros, K.; Paik, D.; Motiwala, R.; Weinberger, J.; Zhou, L. & Shin, S. Median nerve penetration by a persistent median artery and vein mimicking carpal tunnel syndrome. *Muscle Nerve.* 53(3):485-7, 2016.
- Sthapak, E.; Gajbe, U. & Singh, B. R. Study of communication between musculocutaneous and median nerves in man. *J. Anat. Soc. India*, 67(Suppl. 2):S37-S44, 2018.
- Sulaiman, S.; Soames, R. & Lamb, C. The sensory distribution in the dorsum of the hand: anatomical study with clinical implications. *Surg. Radiol. Anat.*, 37(7):779-785, 2015.
- Tamagawa, C.; Shiga, K.; Ohshima, Y.; Tokunaga, D. & Nakagawa, M. Riche-Cannieu anastomosis and a paradoxical preservation of thenar muscles in carpal tunnel syndrome: a case report. *No To Shinkei*, 56(1):53-8, 2004.
- Tricco, A. C.; Lillie, E.; Zarin, W.; O'Brien, K. K.; Colquhoun, H.; Levac, D.; Moher, D.; Peters, M. D. J.; Horsley, T.; Weeks, L.; et al. PRISMA extension for scoping reviews (PRISMA-ScR): checklist and explanation. *Ann. Intern. Med.*, 169(7):467-73, 2018.
- Troupis, T.; Michalinos, A.; Protogerou, V.; Mazarakis, A. & Skandalakis, P. Complex anatomic variation in the brachial region. *Folia Morphol. (Warsz.)*, 74(1):118-21, 2015.
- Tryfonidis, M.; Jass, G. K.; Charalambous, CP. & Jacob, S. Superficial branch of the radial nerve piercing the brachioradialis tendon to become subcutaneous: an anatomical variation with clinical relevance. *Hand Surg.*, 9(2):191-5, 2004.
- Upton, A. R. & McComas, A. J. The double crush in nerve-entrapment syndromes. *Lancet*, 2(7825):359-62, 1973.
- Venieratos, D. & Anagnostopoulou, S. Classification of communications between the musculocutaneous and median nerves. *Clin. Anat.*, 11(5):327-31, 1998.
- von Schroeder, H. P. & Scheker, L. R. Redefining the "Arcade of Struthers". *J. Hand Surg. Am.*, 28(6):1018-21, 2003.
- Wang, C. K. & Ng, C. Y. Accessory flexor carpi ulnaris: açç rare cause of distal ulnar nerve compression. *J. Hand Surg. Eur. Vol.*, 46(2):197-9, 2021.
- Wertsch, J. J. & Melvin, J. Median nerve anatomy and entrapment syndromes: a review. *Arch. Phys. Med. Rehabil.*, 63(12):623-7, 1982.
- Willan, P. L. & Humpherson, J. R. Concepts of variation and normality in morphology: important issues at risk of neglect in modern undergraduate medical courses. *Clin. Anat.*, 12(3):186-90, 1999.
- Won, H. S.; Oh, C. S. & Chung, I. H. A split and conjoined median nerve in the forearm. *Anat. Sci. Int.*, 85(2):115-7, 2010.
- Wynter, S. & Dissabandara, L. A comprehensive review of motor innervation of the hand: variations and clinical significance. *Surg. Radiol. Anat.*, 40(3):259-69, 2018.
- Xianyu, M.; Zhenggang, B. & Laijin, L. Identification of the sensory and motor fascicles in the peripheral nerve: A historical review and recent progress. *Neurol. India*, 64(5):880-5, 2016.

Corresponding author:

Aldo Scafoglieri
Experimental Anatomy Research Group
Faculty of Physical Education and Physiotherapy
Vrije Universiteit Brussel
Laarbeeklaan 103
1090 Brussels
BELGIUM

E-mail: aldo.scafoglieri@vub.be